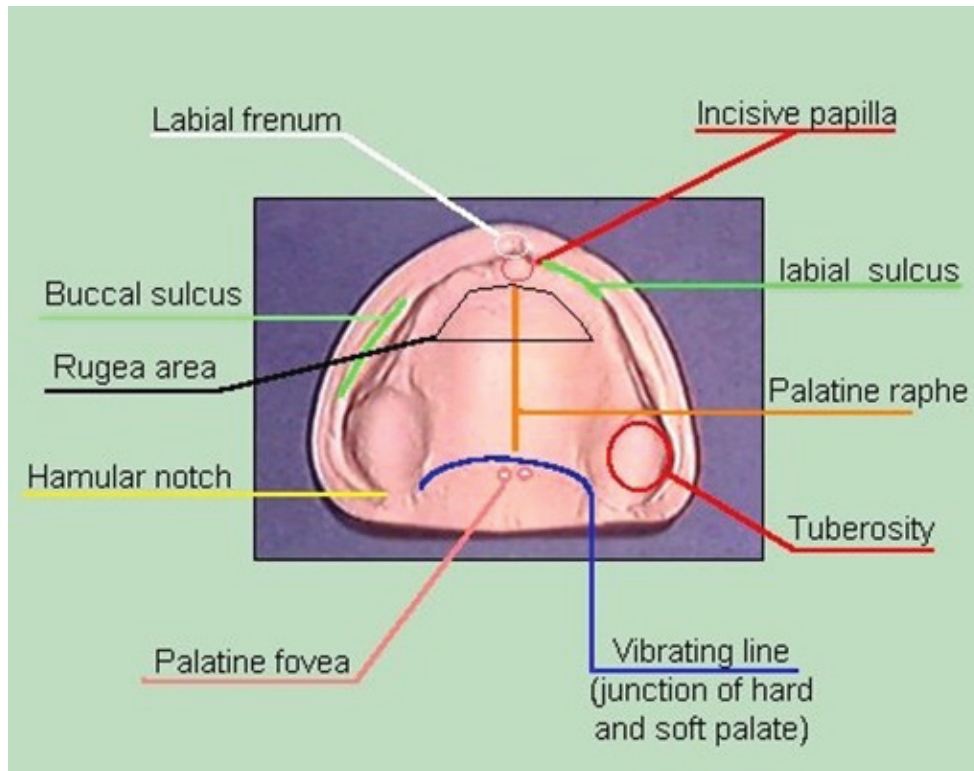


Standard impression landmark

Indicating the areas to capture when taking an edentulous impression

Maxilla



Mandible

